

Management and Discussion of COVID-19 Related Tracheal Stenosis: A Single Center Retrospective Review

Alexander J Sweidan, Haron Y Anaim , Niral M Patel, Javier A Longoria

Division of Pulmonary and Critical Care Medicine, Interventional Pulmonary, University of California, Irvine, CA, USA

Correspondence: Alexander J Sweidan, Division of Pulmonary and Critical Care Medicine, Interventional Pulmonary, University of California, 101 The City Dr S, Orange, CA, 92868, USA, Tel +1 714-456-5413, Email asweidan@hs.uci.edu

Abstract: SARS-CoV-2 virus has led to an unprecedented amount of tracheal stenosis. Rigid bronchoscopy can serve as a curative measure or bridge therapy to tracheal resection. We also briefly discuss the pathophysiology of tracheal stenosis from prolonged intubation and SARS-CoV-2 virus. This should be differentiated from other forms of airway obstruction such as tracheobronchomalacia which would be considered a pseudo-tracheal stenotic disease. The aim of this study is to evaluate stenosis that is unable to be improved with positive airway pressure or “PAP” therapies and required stenting and/or subsequent tracheal resection. By performing Rigid Bronchoscopy and subsequent stenting of airways, we demonstrated outcomes for long term airway patency regarding patients who were intubated secondary to the SARS-CoV-2 virus. We demonstrate superb outcomes in a consecutive case series of 6 patients managed with rigid bronchoscopy, airway stent and tracheal resection. The patients were all managed from a pulmonary perspective by the physicians mentioned in this study.

Keywords: tracheal stenosis, COVID-19 intubation, rigid bronchoscopy

Introduction

Tracheal stenosis is defined as an abnormal narrowing or stricture within the tracheal lumen, see [Figure 7](#) for reference. This leads to obstruction in the central airway and can be life-threatening if it is not recognized and treated in a time sensitive manner. Tracheal stenosis is mostly caused by malignancy, but many nonmalignant etiologies exist, including stricture formation following endotracheal intubation and/or tracheostomy placement. The pathogenesis underlying post-intubation or post-tracheostomy tracheal stenosis involves airway inflammation and intrinsic vascular compression by the inflated cuff of the endotracheal or tracheostomy tube.¹ In patients with severe COVID-19 disease that develop ARDS requiring mechanical ventilation, there are increasing reports of prolonged need for mechanical ventilation, a known risk factor for the later development of tracheal stenosis. Coronavirus disease 2019 (COVID-19) caused by severe acute respiratory syndrome coronavirus 2 (SARS-CoV-2) is a multi-system disorder that causes a pro-inflammatory state that can lead to acute respiratory distress syndrome (ARDS).

Table 1 Cases 1–6 Including Age, Sex, Days Under Care, Comorbidities

Case 1	47	Woman	58 days (18 I, 40 T)	Type 2 Diabetes Mellitus, Diabetic Ketoacidosis
Case 2	63	Man	14 days (14 I, 0 T)	Hypertension, end-stage renal disease
Case 3	45	Woman	66 days (13 I, 53 T)	Crohn's disease on immunosuppressant therapy
Case 4	42	Man	8 days (8 I, 0 T)	Type 2 diabetes mellitus, diabetic ketoacidosis
Case 5	34	Woman	67 days (25 I, 42 T)	Severe obesity, type 2 diabetes mellitus, eosinophilic asthma
Case 6	65	Woman	8 days (8 I, 0 T)	Chronic obstructive pulmonary disease, type 2 diabetes mellitus, end-stage renal disease

Abbreviations: I, intubated; T, trached.

In this case series, we report six patients who developed ARDS due to COVID-19, underwent endotracheal intubation for mechanical ventilation, with four patients going on to receive tracheostomy tube placement before eventual decannulation. All six patients later presented with nonspecific symptoms and were diagnosed with tracheal stenosis. We aim to show that patients with tracheal stenosis due to COVID-19 infection can be successfully managed using tracheal dilation.

Methods

We performed a retrospective review between December 2020 and November 2021 for all new cases of tracheal stenosis at the University of California, Irvine. Of these cases, 6 of 20 (30%) had tracheal stenosis related to COVID-19 that eventually underwent rigid bronchoscopy, tracheal dilation, and/or tracheal resection (Table 2). All cases had a Myer-Cotton grade of laryngeal stenosis of at least 3 (71% to 99% obstruction) at the time of dilation (Table 1).

Table 2 Pathogenesis of Disease Burden and Prevention Taken Respectively

Pathogenesis	Prevention
COVID-19 induces a profound pro-inflammatory cascade referred to as a cytokine storm leading to tissue damage. ¹	Tocilizumab, an interleukin-6 inhibitor, may be used to reduce inflammation. ¹
The cuff of the endotracheal tube inflates and deflates daily for weeks. Moreover, the rigid tube is moved and assessed for cuff leaks. The constant external pressure eventually causes tracheal irritation and fibrosis via biomechanical stress. ² Persistent mechanical tension also leads to defective TGF- β signaling and enhances the fibrotic cascade.	Prolonged tracheal irritation may be alleviated with a tracheostomy tube if it can be done safely (with minimal risk of aerosol cross-infection). This may be an effective tool to facilitate ventilator weaning. ³
Repeated intubations may be needed if the first attempt is not successful, especially in patients with different anatomic variants. They cause repeated physical trauma to the trachea.	Video-assisted laryngoscopy may successfully reduce the number of intubation attempts compared to direct laryngoscopy and minimize risk of esophageal intubation. ⁴
The cuff of the endotracheal tube tightly seals the endotracheal tube to the trachea constantly exerting pressure and stopping circulation to the tracheal wall causing local ischemia and eventually scar formation. Due to the lack of blood flow, tissue damage continues. ⁵	The pressure of the cuff of the endotracheal tube should be reduced to allow for local blood flow and replenish nutrients to the area. ⁶ Cuff pressures should be inflated to 20 to 30 mm H ₂ O. Pressures greater than 30 mm H ₂ O have been associated with venous stasis, which sets forth the pathway to tracheal stenosis. Oversized tube diameters should be avoided. In obese patients, consider tracheostomy tubes with an extended proximal limb rather than a larger diameter tube. ⁷ Control of comorbidities is also important, as patients with underlying diabetes mellitus and cardiovascular disease may have microvascular changes that put them at increased risk for tissue ischemia.
The growth of granulation leads to delayed airway stenosis and causes patients to come to the hospital about a month after they are discharged home after being intubated and in the intensive care unit for weeks.	Patient education on signs of tracheal stenosis before discharge with the instruction to seek medical attention quickly may expedite the diagnosis of TS. An intralesional steroid injection, topical mitomycin C or 5-fluorouracil/triamcinolone, may prevent severe tracheal stenosis due to their anti-fibrotic and anti-inflammatory properties. ^{8,9}
Gastroesophageal reflux may cause and exacerbate laryngeal damage. ¹⁰	Both lifestyle and pharmacologic interventions to prevent gastroesophageal reflux may help to reduce the risk of developing tracheal stenosis. In the critical care setting, it is important to consider prevention against tracheal stenosis in addition to stress ulcer formation as an indication for prophylactic acid suppression.

Tracheal Dilation

Tracheal dilation, steroid injections, and tracheal stenting were performed using rigid bronchoscopy. Tracheal dilation was performed with radial incisions made with potassium-titanium-phosphate (KTP) laser bronchoscopy in the stenosis. Serial dilation with increasing sizes of a rigid bronchoscope was performed using the bevel. This was done until the 10mm or 12mm rigid bronchoscope could be passed beyond the stenosis. Once achieved, the bronchoscope was allowed to dilate the airway for at least 5 minutes. Steroid injections were performed with triamcinolone acetonide 40 mg/mL. Tracheal stenting was performed with hourglass-shaped silicone stents.

Case 1

A 47-year-old woman with a relevant history of morbid obesity and poorly-controlled type 2 diabetes mellitus developed COVID-19 pneumonia in December 2020 and required mechanical ventilation at an outside hospital. A tracheostomy was performed 13 days after initial intubation. She was transferred to a long term acute care facility where she was eventually decannulated and later discharged to a skilled nursing facility. Approximately 13 weeks later, she developed dyspnea and upper airway stridor. Flexible bronchoscopy revealed at the first tracheal ring a grade 3, concentric, corkscrew-type stenosis (Figure 1), which was just cephalad to where her tracheostomy tube had been placed. The level of her tracheostomy was widely patent. She was taken to the OR and dilated up to 10mm. After the procedure she was discharged home on room air.

Case 2

A 63-year-old man with a relevant history of obesity and end-stage renal disease due to poorly controlled hypertension developed COVID-19 pneumonia in September 2020 requiring mechanical ventilation for 14 days. His hospital course was further complicated by pulmonary embolism requiring anticoagulation. He was transferred to an acute rehabilitation unit. Approximately 8 weeks later, he developed dyspnea and upper airway stridor. Flexible bronchoscopy revealed grade 3 tracheal stenosis at the level of the cricoid cartilage and first tracheal ring, there was a long complex corkscrew-type stenosis extending 3 tracheal rings (Figure 2). The narrowest point of stenosis measured 3 mm in length. Using the rigid bronchoscope, we were able to dilate the stenosis up to 12 mm. He was eventually discharged home on room air.

Case 3

A 45-year-old woman with a relevant history of Crohn's disease on immunosuppression developed COVID-19 pneumonia in November 2020. She required mechanical ventilation and eventual tracheostomy. She was transferred to a long-term acute care facility where she improved and was successfully decannulated with minimal post-decannulation supplemental oxygen requirements via nasal cannula. Approximately 20 weeks later, she presented with increasing oxygen requirements and dyspnea. Flexible bronchoscopy revealed grade 3 tracheal stenosis at the level of the third tracheal ring and extending 2 rings, there was severe concentric corkscrew-type stenosis that tapered down to approximately 3 to 4 mm (Figure 3). By way of rigid bronchoscopy, the airway was dilated up to 12 mm with gentle dilation. In

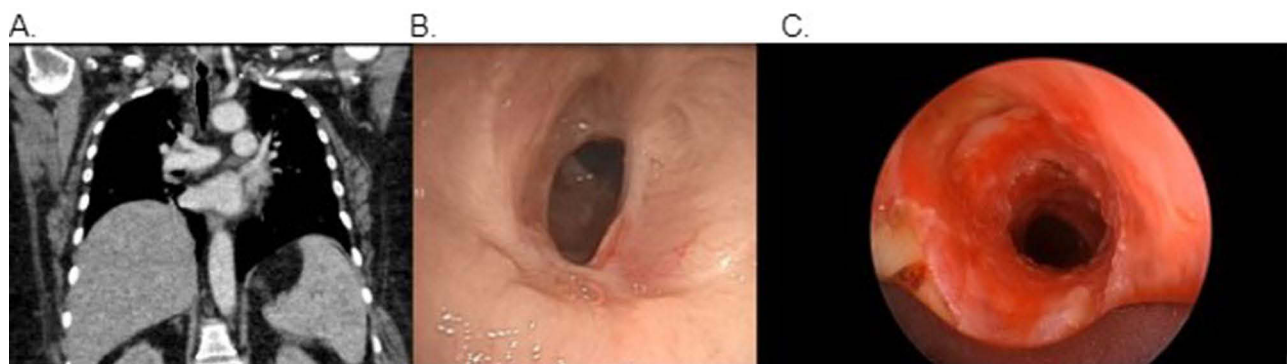


Figure 1 Grade 3, concentric, corkscrew-type stenosis seen on CT chest (A) and pre-dilation bronchoscopy (B). Post-dilation bronchoscopy reveals airway patency (C).

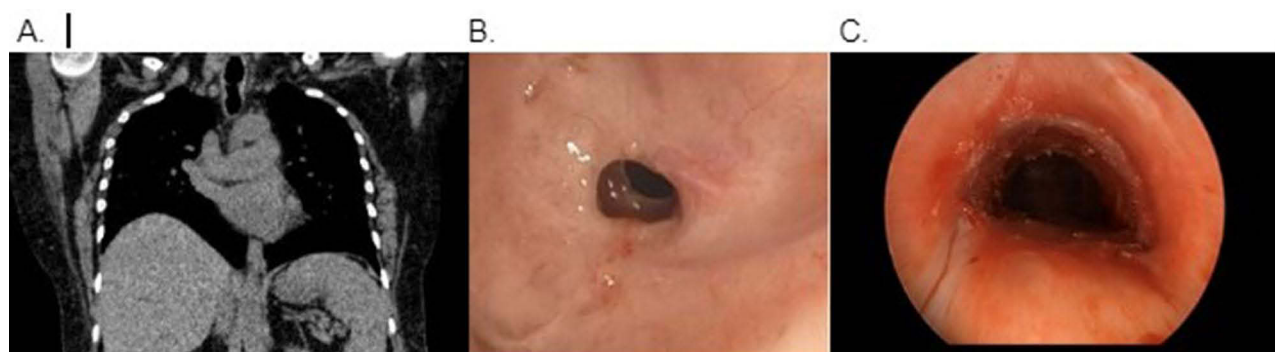


Figure 2 Grade 3, complex corkscrew-type stenosis which extended 3 tracheal rings seen on CT chest (A) and pre-dilation bronchoscopy (B). Post-dilation bronchoscopy reveals airway patency (C).

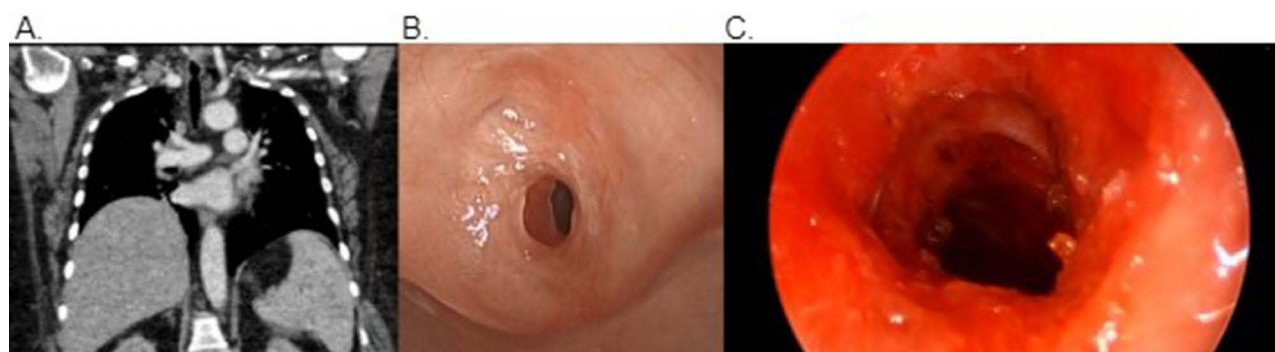


Figure 3 Grade 3, concentric, corkscrew-type stenosis which extended at least 2 tracheal rings seen on CT chest (A) and pre-dilation bronchoscopy (B). Post-dilation bronchoscopy reveals airway patency (C).

addition, we injected 40 mg of triamcinolone acetonide into the lesion at the area of stenosis. She recovered in the postop unit and was discharged home on room air. She was eventually seen by our Thoracic Surgery colleagues and underwent successful and definitive tracheal resection.

Case 4

A 42-year-old woman with a relevant history of obesity and type 2 diabetes mellitus developed diabetic ketoacidosis with coma and was found to have COVID-19 pneumonia in October 2020. She was intubated for 8 days at an outside hospital then successfully weaned off mechanical ventilation and extubated without need for tracheostomy. In December 2020, she was found to have tracheal stenosis by flexible bronchoscopy performed by an outside pulmonologist who treated her with oral steroids and referred her to our facility. Starting at the third to fourth tracheal ring at the level of the thoracic inlet, there was a grade 3, complex, concentric stenosis that narrowed down to approximately 2 to 3 mm (Figure 4). The airway was dilated up to 12 mm for approximately 5 minutes. It was clear that due to the length of the stenosis and the relative firmness this would re-stenose quite quickly if a stent was not placed. Therefore, a 14×12 x 14 mm silicone studded hourglass stent that was 4 cm in length was loaded. It was deployed into the distal trachea and positioned such that the stent covered and dilated the entirety of the stenosis. The procedure was then terminated, the patient woke up without incidence and recovered in the postop unit to eventually be discharged home on room air.

Case 5

A 34-year-old woman with a relevant history of severe morbid obesity, type 2 diabetes mellitus, and eosinophilic asthma developed COVID-19 pneumonia in July 2020 and required intubation for acute respiratory distress syndrome. Her hospital course was complicated by left lower extremity deep venous thrombosis requiring thrombectomy. Her ventilator

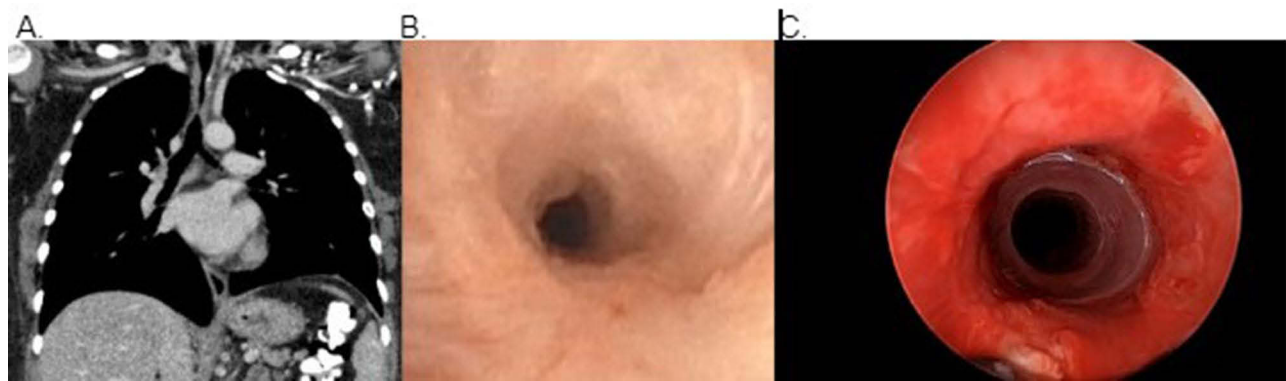


Figure 4 Grade 3, complex, concentric stenosis seen on CT chest (A) and pre-dilation bronchoscopy (B). Post-procedure bronchoscopy reveals airway patency with silicone studded hourglass stent in place (C).

requirements improved, and a tracheostomy was performed at an outside hospital. She was transferred to a long-term acute care facility where she was eventually decannulated. She presented 17 weeks later with dyspnea. Given her known history of asthma, she was prescribed multiple courses of oral steroids and her inhaler therapy was escalated. Eventually, a computed tomography (CT) scan of the chest revealed tracheal stenosis. At the first tracheal ring, there was a grade 3 stenosis that tapered down to a diameter of 5 mm and extended another 2 tracheal rings (Figure 5). The airway was dilated up to 10 mm with the rigid bronchoscope for over 5 minutes. The patient woke up without incident and recovered in the post anesthesia care unit to eventually be discharged home on room air.

Case 6

A 65-year-old man with a relevant history of chronic obstructive pulmonary disease and type 2 diabetes mellitus developed COVID-19 pneumonia and required intubation in Mexico in December 2020. He was intubated for approximately 8 days. He presented to our facility in March 2021 with dyspnea and biphasic stridor. Flexible bronchoscopy revealed a grade 3 tracheal stenosis (Figure 6). He was dilated for over 10 minutes with the 12 mm diameter rigid bronchoscope. He was then extubated from the rigid bronchoscope and woke up in the operating theater uneventfully and discharged home the same day on room air.

Discussion

Stenosis can occur at any level of the airway, but it is most commonly identified at the level of a prior tracheostomy stoma and at the level of the prior balloon cuff or distal end of a prior tube in the setting of post-intubation or post-

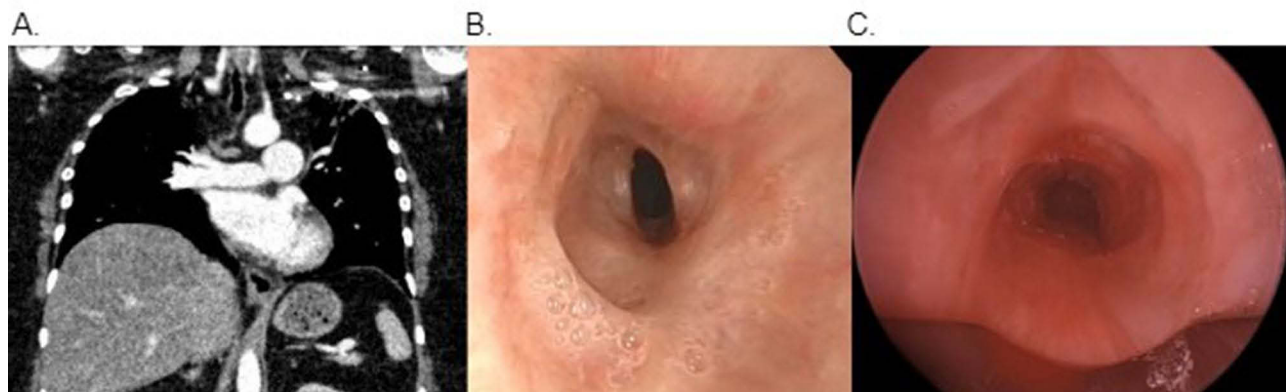


Figure 5 Grade 3, oval, corkscrew-type stenosis which extended 2 tracheal rings seen on CT chest (A) and pre-dilation bronchoscopy (B). Post-dilation bronchoscopy reveals airway patency (C).

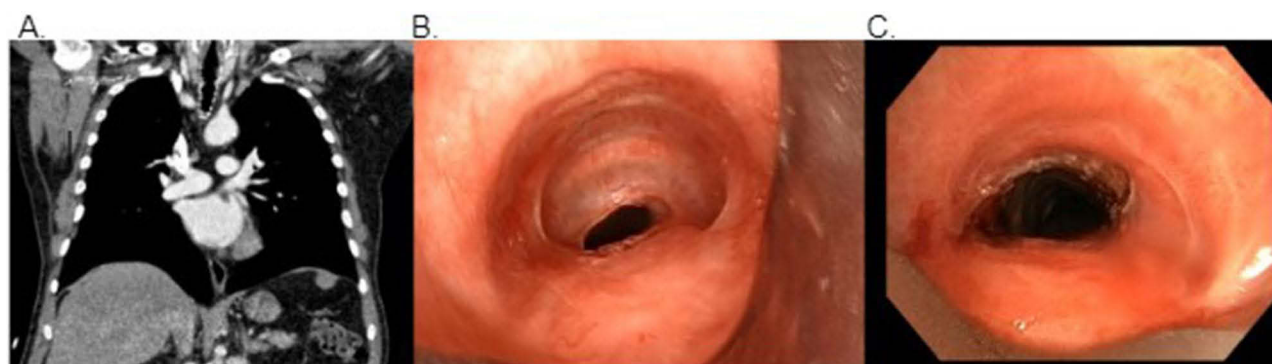

Figure 6 Grade 3, concentric stenosis seen on CT chest (A) and pre-dilation bronchoscopy (B). Post dilation bronchoscopy reveals airway patency (C).

tracheostomy tracheal stenosis.¹¹ In the aim of this study we evaluated 6 cases of COVID-19 related tracheal stenosis as listed. It is believed that an abnormal healing process contributes to the development of tracheal stenosis,¹² beginning when mucosal ulceration causes necrosis and absorption of underlying cartilage. Stenosis at the stomal level is related to the anterior tracheal wall defect created for the tracheostomy. This results in excess granulation tissue formation around the stoma site.¹³ Pressure ischemia may occur when higher amounts of pressure are placed along stomal margins, the larger the tracheostomy tube, the greater the amount of pressure applied. Similarly, mechanical pressure due to unsupported ventilator hose attachments can further lead to ischemia and can later develop into necrosis. Decannulation allows the cartilage around the stoma to heal by fibrosis. In contrast, stenoses at the cuff level are felt to be related to local circumferential or patchy ischemia caused by the pressure created by the cuff onto the tracheal wall.¹⁴ This process is thought to begin within the first few hours post intubation.¹³ Stenoses are graded via the Myer-Cotton system, see Figure 7. It should be noted that tracheobronchomalacia can lead to a pseudo-tracheal stenosis however, since the airway remains patent on inspiration this is not a true tracheal stenosis. Positive end expiratory pressure would maintain pathway for a patent airway therefore not making tracheal malacia the same as a true tracheal stenosis.

Patients who are critically ill with COVID-19 often require endotracheal intubation and mechanical ventilation to treat acute respiratory distress syndrome (Table 2). An early report by Huang et al demonstrated that invasive mechanical ventilation was required in 9.8 to 15.2% of patients with COVID-19. For these patients, mechanical ventilation is a lifesaving intervention to allow time for lung recovery while hospitalized, with a median of 17 ventilator days and a high frequency of re-intubation needs.¹⁶ Tracheal injury related to endotracheal intubation is a known complication in cases where prolonged periods of mechanical ventilation are required, making tracheal stenosis a more common complication in the COVID-19 patient population.

In a retrospective study by Fiacchini et al, 14 out of 30 COVID-19 patients who underwent invasive mechanical ventilation for 14 or more days developed full-thickness tracheal lesions or tracheoesophageal fistulas.¹⁷ In contrast, only 1 patient in the control group, which consisted of 45 patients without COVID-19, had a full-thickness tracheal lesion (Table 1). While subglottic or tracheal stenosis and tracheoesophageal fistulas are known complications of endotracheal intubation, they are rare with only 0.3 to 3% developing it from prolonged invasive mechanical ventilation in patients without COVID-19.¹⁸ Acute laryngeal injury occurs in 57% of patients during the placement of the tube, which then results in ulceration or granulation tissue formation.¹⁹ The risk factors for tracheal stenosis include prolonged intubation,^{20,21} use of high-pressure low-volume cuffs,¹⁴ large diameter tracheostomy tubes,¹⁴ high-dose steroid use greater than prednisone 30 mg per day or equivalent,^{13,14} female gender,¹³ as well as obesity, diabetes mellitus, and cardiovascular disease.²² Unfortunately, many of these risk factors coincide with the patient population that suffer from severe COVID-19 infection, placing them at even greater risk of post-intubation tracheal stenosis.²³

While the understanding of the pathogenesis of post-intubation tracheal stenosis specific to COVID-19 is not entirely clear, we believe it may be caused by a combination of these 5 factors: a severe proinflammatory state, tracheal irritation from prolonged presence of an endotracheal tube, decreased tracheal blood flow, granulation tissue growth, and

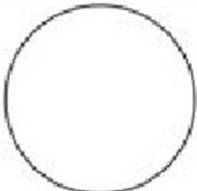
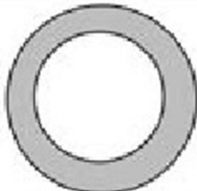
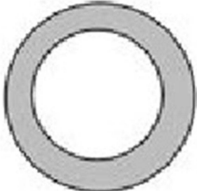
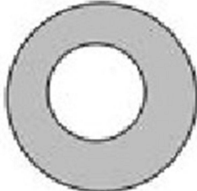
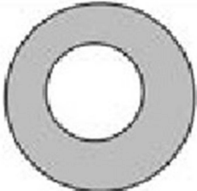
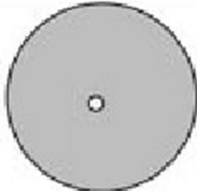
Classification of obstruction	From	To
Grade I	 0%	 50%
Grade II	 51%	 70%
Grade III	 71%	 99%
Grade IV	No detectable lumen	

Figure 7 Classification grading demonstrating various levels of stenosis of the lumen based on the Meyer's Cotton system.¹⁵

gastroesophageal reflux which further contributes to tracheal injury. These points with explanations and potential interventions are summarized in Table 2.

Post-intubation tracheal stenosis related to COVID-19 has been reported by other physicians. Li et al found that otolaryngologists performing tracheostomies by creating a Bjork flap have a lower incidence of post-tracheostomy tracheal stenosis. Although percutaneous tracheostomy is known to be a safe technique, patients who are obese or with poor landmarks may benefit more from an open technique placement.⁷ Vasanthan et al reported the complication in a 71-year-old female who presented with worsening “breathlessness and added airway sounds” 36 days post-discharge after a 35-day admission for COVID-19 pneumonia.²⁴ Mattioli et al reported 19 patients with tracheal stenosis and treated them endoscopically with balloon dilation.²⁵

The long term follow-up results of this study have not been documented due to the fact that none of the aforementioned authors have remained as full time faculty at the University of California, Irvine. It should also be noted that there has been a recurrence rate of 26% found by Zias et al and further evaluation and management of these patients is essential. There is some concern for restenosis of these patients after initial stenosing. As for the recurrence of stenosis, all patients in this study were referred back to the Interventional Pulmonary Department at the University of California,

Irvine for close follow up and if stenosis was again noted patients were taken for repeat rigid-bronchoscopy and their airway made patent again. r.

Conclusion

In our institution, we have observed that patients that were infected with COVID-19 and who required intubation for more than 14 days may recover from the COVID-19 infection to eventual extubation or decannulation in cases where tracheostomy was performed; however, these patients developed symptomatic tracheal stenosis weeks later. Symptoms upon presentation include but are not limited to stridor, dyspnea, wheezing, drowsiness, coughing, and cyanosis of the lips. These symptoms can develop in patients in an acute or subacute period. The nature of the symptoms is nonspecific and may be mistaken for other common pulmonary diseases (such as asthma, chronic obstructive pulmonary disease, pneumonia and bronchitis). Due to this we highly encourage both physicians and patients to be conscious of tracheal stenosis as a differential when evaluating complications of post-intubation related to COVID-19. This will allow for better care and management to be directed accordingly. Suspected cases can be worked up with chest imaging and pulmonary function tests; however, abnormalities seen on these modalities are neither sensitive nor specific to tracheal stenosis. The gold standard to best demonstrate the stenotic lesion is direct visualization via bronchoscopy. Notably, the incidence of tracheal stenosis may be higher than reported given there are no routine follow-up airway examinations to screen for asymptomatic tracheal stenosis. It may be difficult to determine timelines for recurrence of tracheal stenosis given asymptomatic presentations. Thus there is utility in serial bronchoscopies or other endoscopic treatments, specifically dilations, to better manage the patients' airway obstructions. The severity of obstruction and ultimately response to initial therapy would determine recurrence and it should be noted there is expected varying outcomes in timeline in regards to how frequently recurrence of stenosis may occur. At our center, we treat symptomatic tracheal stenosis by entering the trachea with a rigid bronchoscope, possible laser and electrocautery followed by dilation. Other centers have reported success with treating tracheal stenosis with cryotherapy by either cryotherapy probe and/or cryospray.²⁶ These interventional methods have yielded excellent results and better outcomes for our patients.

Ethics and Consent Statements

No identifiable patient information was disclosed. Appropriate ethical procedures were followed to ensure patient privacy. Institutional approval was obtained from the University.

All patients or their durable power of attorney included in this case series provided written or verbal informed consent to publish the data presented in this manuscript. All written and verbal consent was documented at the time and stored within EMR of the patient.

Acknowledgments

Publishing of these findings was directly allowed under the Division of Pulmonary and Critical Care Medicine at University of California, Irvine.

Authors Contributions

All authors made a significant contribution to the work reported, whether that is in the conception, study design, execution, acquisition of data, analysis and interpretation, or in all these areas; took part in drafting, revising or critically reviewing the article; gave final approval of the version to be published; have agreed on the journal to which the article has been submitted; and agree to be accountable for all aspects of the work.

Disclosure

The authors report no conflicts of interest in this work.

References

1. Andrews MJ, Pearson FG. Incidence and pathogenesis of tracheal injury following cuffed tube tracheostomy with assisted ventilation: analysis of a two-year prospective study. *Ann Surg*. 1971;173(2):249–263. doi:10.1097/00006558-197102000-00012

2. Hojyo S, Uchida M, Tanaka K, et al. How COVID-19 induces cytokine storm with high mortality. *Inflam Regener*. 2020;40(1). doi:10.1186/s41232-020-00146-3
3. Dees C, Zerr P, Tomcik M, et al. Inhibition of notch signaling prevents experimental fibrosis and induces regression of established fibrosis. *Arthritis Rheum*. 2011;63(5):1396–1404. doi:10.1002/art.30254
4. Courtney A, Lignos L, Ward PA, Vizcaychipi MP. Surgical tracheostomy outcomes in COVID-19–positive patients. *OTO Open*. 2021;5(1):2473974X2098499. doi:10.1177/2473974X20984998
5. Mosier JM, Whitmore SP, Bloom JW, et al. Video laryngoscopy improves intubation success and reduces esophageal intubations compared to direct laryngoscopy in the medical intensive care unit. *Critical Care*. 2013;17(5):R237. doi:10.1186/cc13061
6. Halum SL, Ting JY, Plowman EK, et al. A multi-institutional analysis of tracheotomy complications. *Laryngoscope*. 2012;122(1):38–45. doi:10.1002/lary.22364
7. Mathias DB, Wedley JR. The effects of cuffed endotracheal tubes on the tracheal wall. *Br J Anaesth*. 1974;46(11):849–852. doi:10.1093/bja/46.11.849
8. Li M, Yiu Y, Merrill T, Yildiz V, deSilva B, Matrk L. Risk factors for posttracheostomy tracheal stenosis. *Otolaryngology*. 2018;159(4):698–704. doi:10.1177/0194599818794456
9. Cincik H, Gungor A, Cakmak A, et al. The effects of mitomycin C and 5-fluorouracil/ triamcinolone on fibrosis/scar tissue formation secondary to subglottic trauma (experimental study). *Am J Otolaryngol*. 2005;26(1):45–50. doi:10.1016/j.amjoto.2003.07.002
10. Raman T, Chatterjee K, Alzghoul BN, et al. A bronchoscopic approach to benign subglottic stenosis. *SAGE Open Med Case Rep*. 2017;5:2050313X1771315. doi:10.1177/2050313x17713151
11. Koufman JA. The otolaryngologic manifestations of Gastroesophageal Reflux Disease (GERD): a clinical investigation of 225 patients using ambulatory 24-hour pH Monitoring and an experimental investigation of the role of acid and pepsin in the development of laryngeal. *Laryngoscope*. 1991;101(4):1–78. doi:10.1002/lary.1991.101.s53.1
12. Dorris ER, Russell J, Murphy M. Post-intubation subglottic stenosis: aetiology at the cellular and molecular level. *Eur Respir Rev*. 2021;30(159):1–15. doi:10.1183/16000617.0218-2020
13. Zias N, Chroniou A, Tabba MK, et al. Post tracheostomy and post intubation tracheal stenosis: report of 31 cases and review of the literature. *BMC Pulm Med*. 2008;8. doi:10.1186/1471-2466-8-18
14. Sandhu GS, Nouraei SAR, Nouraei SM. *Pathophysiology of Laryngotracheal Stenosis*. Plural Publishing Inc.; 2016.
15. Myer CM, O'Connor DM, Cotton RT. Proposed grading system for subglottic stenosis based on endotracheal tube sizes. *Ann Otol Rhinol Laryngol*. 1994;103(4):319–323. doi:10.1177/000348949410300410
16. Yang X, Yu Y, Xu J, et al. Clinical course and outcomes of critically ill patients with SARS CoV-2 pneumonia in Wuhan, China: a single-centered, retrospective, observational study. *Lancet Respir Med*. 2020;8(5):475–481. doi:10.1016/S2213-2600(20)30079-5
17. Fiacchini G, Tricò D, Ribecchini A, et al. Evaluation of the incidence and potential mechanisms of tracheal complications in patients with COVID-19. *JAMA Otolaryngol*. 2021;147(1):70–76. doi:10.1001/jamaoto.2020.4148
18. Bibas BJ, Cardoso PFG, Minamoto H, Pêgo-Fernandes PM. Surgery for intrathoracic tracheoesophageal and bronchoesophageal fistula. *Ann Translat Med*. 2018;6(11):210. doi:10.21037/atm.2018.05.25
19. Shinn JR, Kimura KS, Campbell BR, et al. Incidence and outcomes of acute laryngeal injury after prolonged mechanical ventilation*. *Crit Care Med*. 2019;47(12):1699–1706. doi:10.1097/CCM.0000000000004015
20. Cakir E, Atabek AA, Calim OF, et al. Post-intubation subglottic stenosis in children: analysis of clinical features and risk factors. *Pediatr Int*. 2020;62(3):386–389. doi:10.1111/ped.14122
21. Manica D, Schweiger C, Maróstica PJC, Kuhl G, Carvalho PRA. Association between length of intubation and subglottic stenosis in children. *Laryngoscope*. 2013;123(4):1049–1054. doi:10.1002/lary.23771
22. Nicolli EA, Carey RM, Farquhar D, Haft S, Alfonso KP, Mirza N. Risk factors for adult acquired subglottic stenosis. *J Laryngol Otol*. 2017;131(3):264–267. doi:10.1017/S0022215116009798
23. Al-Sabah S, Al-Haddad M, Al-Youha S, Jamal M, Almazeedi S. COVID –19: impact of obesity and diabetes on disease severity. *Clin Obes*. 2020;10(6). doi:10.1111/cob.12414
24. Vasanthan R, Sorooshian P, Sri Shanmuganathan V, Al-Hashim M. Laryngotracheal stenosis following intubation and tracheostomy for COVID-19 pneumonia: a case report. *J Surg Case Rep*. 2021;2021(1):3. doi:10.1093/jscr/rjaa569
25. Mattioli F, Marchioni A, Andreani A, Cappiello G, Fermi M, Presutti L. Post-intubation tracheal stenosis in COVID-19 patients. *Europ Arch Oto*. 2021;278(3):847–848. doi:10.1007/s00405-020-06394-w
26. Ratwani A, Fernando H, Khandhar SJ, Mahajan AK. Review of advanced airway cryosurgical techniques. *Curr Respir Med Rev*. 2017;13(2). doi:10.2174/1573398X13666170828111043